

# Automatic Segmentation of the Spinal Cord Using Image Processing Techniques- A Survey

Dr.R.Priya <sup>1</sup>, Umaibanu M <sup>2</sup>

<sup>1</sup> HOD & Associate Professor, Department of Computer Science, Sree Narayana Guru College, Coimbatore, Tamil Nadu, India

<sup>2</sup> M.Phil Scholar, Department of Computer Science, Sree Narayana Guru College, Coimbatore, Tamil Nadu, India

**Abstract** – Medical image processing is an important area of recent research. This facilitates the clinician to diagnosis, analyze, prognosis traumatic diseases. There are many types of human body parts are analyzed to evaluate the diseases or discomforts in the human body. These analysis, diagnosis are processed form various image based inputs like Computed Tomography (CT) images, Magnetic Resonance Imaging (MRI) images. Analysis of such images for medical diagnosis needs some deep image processing techniques. Image Segmentation is the main process, which segments the desired object from the scan images. Spinal cord segmentation and analysis of neurodegenerative and traumatic diseases are recently emerging in medical mining tasks. In this paper, a set of image processing techniques and various techniques for spinal cord segmentation is reviewed. This survey finally provides the outline of the earlier researches with the merits and demerits.

**Index Terms** – Image Processing, Spinal cord, spinal canal, CSF, automatic segmentation, vertebral labeling, deformable model, MRI.

## 1. INTRODUCTION

Finding and analyzing the spinal cord with morphological features are more valuable for clinical applications [1]. The morphological features like cross sectional size shape etc. this analysis helps to reduce the risk for surgical complications and other medical supports. This paper gives the overview of the spinal cord segmentation process, techniques and tools used in that in detail. The objective of this paper is to supply an overview of segmentation methods for the human spinal cord and spinal canal which are published recently. First, the general considerations about spinal cord segmentation using MRI acquisition and validation of segmentation algorithms are reviewed. Then, techniques involved with the segmentation for spinal cord and other medical imaging according to their segmentation mechanisms is studied.

### A. Spinal Cord Segmentation and methods:

Spinal cord segmentation is become an important process for automatic interpretation and analysis. But the spinal cord segmentation has several challenges and issues. The shape of the spinal cord is apparently simplistic, but the segmentation can be much complicated due to the improper formation of tissue intensities, image quality oriented issues.

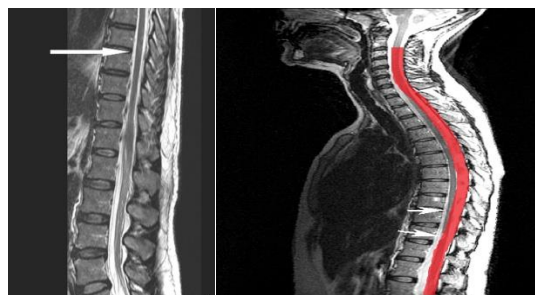

Figure 1.0 Spinal Cord MRI Image Sample

The figure 1.0 shows a sample MRI image and the segmentation of spinal cord. The segmentation of MRI images and finding the morphological features are studied in [2]. Image segmentation can be done on 2D or 3D images manually, semi-automatically or fully automatically. The segmentation process is based on several features and characteristics. The features include the shape, size, prior-shape patterns and edge based. The segmentation methods can be divided into five types shown in figure 2.0.

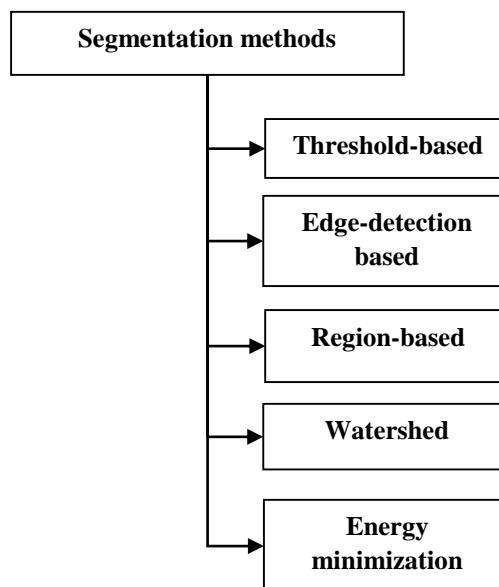


Figure 2.0 Segmentation Methods

The shape of the spinal cord is a long and tabular format; this is very close to many anatomical structures, so segmenting the spinal cord automatically and accurately is more challenging and complicated. To achieve high accuracy and automatic segmentation, many approaches are categorized and proposed. The categories of high-level segmentation methods are learned from [18] and shown in Figure 3.0.

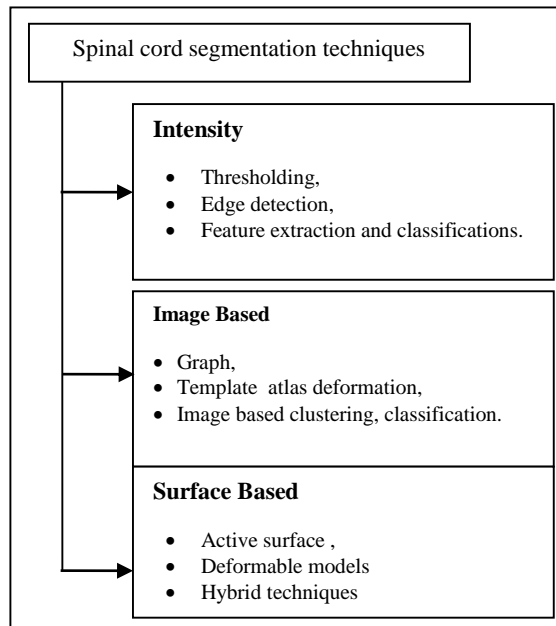


Figure 3.0 High-Level Segmentation Methods

From the high level segmentation methods, the most implementations are carried out. The categories include the intensity, surface and image based segmentation. The branches of classification and segmentation methods are depicted in the figure 3.0.

## 2. LITERATURE REVIEW

In paper [3], authors find the relationship of brain cervical cord volume to find the abnormality and co-morbid conditions of clinical disability. The authors estimated the cervical cord volume, which helps in the clinical monitoring systems. The authors in [4] proposed two algorithms, which contains the intervertebral plate confinement step, and the vertebra identification and division step. In the initial step, authors apply a model-based searching technique to locate all the intervertebral plate pieces of information between neighboring vertebrae of the entire spine and the best cut choice. Another approach utilizing an intensity profile on a polynomial capacity for fitting all these plate pieces or disc clues of information on the best cut is then used to refine the circle seek process. Vertebra focuses are recognized, and starting limits are separated in the second step. The underlying trial of the calculation on the five arrangements of 7 sagittal slices finds each of the 23 intervertebral plate habitats for the best cut of

every one of the five sets. For the assessment of the limit extraction of 22 vertebrae, the calculation effectively finds 100%, 96.6%, 93.2%, 95.5%, 87.5% vertebra corners in image set No.1, 2, 3, 4, and 5, individually. All these preparatory outcomes are fairly promising. A key purpose of the above examinations is to achieve the accuracy. The methodology is totally programmed for the entire spine. Additionally testing on larger information will be required, and extra algorithmic alterations will be expected to suit distinctive varieties as to therapeutic cases, information accumulation procedures and others.

In paper [5], authors measured the cervical spinal cord volume of health users. This evaluates the relationships between the health user's morphological features and abnormal users. Authors consider that the cervical spinal cord volume ratio can be used to evaluate cervical spinal cord atrophy in patients with cervical myelopathy and can be important information in looking for clinically critical points. The cervical spinal cord volume was larger in males than in the females, decreased with age, and increased with height and body weight. The cervical spinal cord volume ratio was not affected by gender, age, height, or body weight.

In paper [6], proposed a combination of segmentation algorithms which combines the object recognition and anatomical knowledge. This allows the system to segment and reconstruct the relevant soft tissue structures at the cervical spine and the vicinity. Authors have shown that automatic, high quality segmentation of soft tissue from MRI images is feasible. The algorithm was tested on nine different T1 and T2 weighted MRI images. The experiments demonstrated the robustness of the algorithms. The computation time for the sample dataset (128 slices of 256 256 pixels) remained under 1 minute on a standard computer. There are still some limits. Currently, the heuristic in the object recognition algorithm relating to the maximum allowed curvature of the spine limits the presented approach to healthy spines and spines with prolapses. Hence, in future work authors will extend the algorithm to support more difficult pathologies, like scoliosis and vertebral deformations due to osteoporosis and fractures. Furthermore, the segmentation process must be constrained for each cervical structure with neighboring anatomy information to avoid overlaps between the resulting 3-D geometric models. This is essential if adjacent or very close cervical structures are examined.

In paper [7], authors proposed an automatic segmentation technique that extracts the spinal cord with MR images of lumbar spine cord datasets; they used a gradient vector flow (GVF) field followed by a connected component analysis for segmentation. MR Images taken from 52 subjects and that are employed to segmentation. This has quantitatively compared against reference segmentation by two medical specialists in terms of a mutual overlap metric. The experimental results

showed that the method achieved better result in terms of segmentation time and accuracy. However, the the segmentation method is not suitable to Computer Aided Diagnosis (CAD) of much lumbar-related pathology. This results in the ineffective segmentation.

In paper [8], Authors have demonstrated a rapid method for segmenting the spinal cord from MR images, and have shown its high inters- and intra observer reproducibility on 3-D T1-weighted images of the human cervical cord. The method needs only modest user interaction, requiring the user to identify landmarks at the extremes of the region of cord to be assessed, and to mark the approximate center-line of the Cord on several slices between the landmarks.

The algorithm is based on a constrained active surface model of the cord surface with a compact parameterization as a center-line and radius generators. This allows rapid segmentation, taking on the order of 1 min, and the cord cross-sectional area can be assessed along the length of the extracted surface. The intra- and inter-observer re producibilities were compared to those of a well-established method for assessing cord atrophy at the C2 level. The new algorithm compared favorably with Losseff's method, at least in part because the cord area was assessed over a larger extent of the cord (approximately 80 mm, compared to the 15 mm of the Losseff method). Nevertheless, when the cord areas were measured over the same anatomical range as is used in the Losseff method, both the intra- and inter observer variability's were still considerably better for the AS method indicating an intrinsic benefit of using a surface model with smoothness constraints.

In paper [9], a variety of medical image segmentation algorithms exists, but seldom is any single algorithm able to address a complex image segmentation problem. In this paper, authors focused on the challenging problem of spinal cord segmentation and made the following observation that allowed us to propose a novel and robust algorithm. Namely, authors observed that different image regions require different algorithm parameter settings, e.g. filtering parameters, and, for those cases, a locally optimal algorithm is ideal. However, local optimality came at a price: missing the global image context. Therefore, authors combined an enhanced crawler method (artificial life segmentation framework with optimal local tubularness filters), with LW (minimal path guaranteeing global optimality). Authors obtained superior results using the hybrid method compared to those without any LW guidance.

In paper [10], authors proposed a topology preserving approach for addressing the automatic segmentation of spinal cord. Spinal cord images are not standard and MR contrast is not optimal always, hence authors described the algorithm to be easily adaptable. So, the construction of necessary atlases from a single manual segmentation and designing has performed. The authors gained more accuracy in the given dataset.

In paper [11], authors presented a new automatic segmentation method named as Propseg. This Propseg improves the accuracy and speed. This overcomes the problem of segmenting of manual method and active surface method. The paper gained successful result on T1-, T2- and T2\*- weighted contrasts with different image resolution. This includes the cervical, lumbar and thoracic spinal cord. However, the technique improves the accuracy, the computational time is high.

In paper [12], authors provided a group wise for segmenting spinal cord internal structure. For the automatic segmentation, a list of techniques was proposed. Pre aligning the slice -based atlases into group wise consistent space, constructing the model of spinal cord variability, the authors used cost function using model specific registration and finally the authors estimated the robust segmentation process.

In paper [13], authors described the framework to develop an unbiased average anatomical template of the spinal cord. This utilizes the non-linear registration and series of pre-processing steps. The template is useful to measure the spinal cord cross sectional area, vertebral levels, voxel based morphometry, white and gray matter location etc., this paper have many advantages and this also incurs more computational overhead. And this is useful only for the defined template.

In paper [14], authors presented morphological characteristics of the complete spinal cord. The paper failed to detect the state of differences in state. Morphological invariants, which could be used to calculate the normally expected morphology accurately, were also identifying. These observations should benefit to biomechanical and spinal cord pathology studies.

In paper [15], proposed an improved method for measuring spinal cord cross-sectional area (CSA) using magnetic resonance imaging (MRI) in multiple sclerosis (MS). In the paper, MRI was performed on many multiple sclerosis patients. At this time point, an additional scan was acquired to evaluate scan-rescan reproducibility.

Two sequences were acquired in the cervical cord: 3D phase sensitive inversion recovery (PSIR) and 3D magnetization prepared rapid acquisition T1- weighted gradient echo. Authors used a semi automated edge detection method and active surface model (ASM) to detect the sensitive regions. Authors evaluated reproducibility for all combinations of sequences and analysis methods using coefficient of variation (COV) and intraclass correlation coefficient and performed sample size calculations for clinical trials to reduce longitudinal cord atrophy.

In paper [16], Authors have presented a novel method for measuring the volume, length, and mean cross-sectional area of sections of the spinal cord from weighted MR images. The MR images like 3D, T1 weighted images are considered. The technique only requires less user input and achieved the maximum reproducible results. The method follows the normal

distribution and measurement errors to detect the partial volume tissue. This paper evaluates the process on sample dataset. And this suffers from mis-classification problems.

### 3. CONCLUSION

The purpose of this paper is to describe the existing methods for segmenting and analyzing the human spinal cord from MRI data. In addition to the methodological description of the segmentation algorithms, the review covered different proposals related to segmentation, including morphological features, image preprocessing, and validation methods. The pros/cons of existing spinal cord segmentation algorithms can be summarized as follows. Intensity-based methods are efficient and fast, but the presence of pathology, artifacts, or poor cord/CSF contrast can yield errors, necessitating user intervention or strategies for regularization. On the other hand, surface-based algorithms and methods based on spinal cord edges are more reliable in the face of such problems because only the image gradients are used for segmentation. Surface-based and energy equation based methods include regularization terms, allowing more robustness against variations in cord/CSF contrast. Multiatlas methods are an interesting avenue for segmenting the cord and/or internal structure. However, a large database with various image contrast, cord shape, and pathology is necessary for these algorithms to perform well. This emphasizes the need for the community to have a shared database that could serve this purpose. In conclusion, there is currently no single method that can adequately segment the cord and its substructure with 100 % robustness. A combination of different approaches is recommended, along with the introduction of probabilistic shape models. Co-registration to dedicated template along with vertebral or spinal cord level identification should also facilitate the segmentation.

### REFERENCES

- [1] Parizel, P. M., T. Van der Zijden, S. Gaudino, M. Spaepen, M. H. J. Voormolen, C. Venstermans, F. De Belder, L. Van Den Hauwe, and J. Van Goethem. "Trauma of the spine and spinal cord: imaging strategies." *European Spine Journal* 19, no. 1 (2010): 8-17.
- [2] Archip, Neculai, P-J. Erard, Michael Egmont-Petersen, J-M. Haefliger, and J-F. Germond. "A knowledge-based approach to automatic detection of the spinal cord in CT images." *IEEE Transactions on Medical Imaging* 21, no. 12 (2002): 1504-1516.
- [3] Lin, X., L. D. Blumhardt, and C. S. Constantinescu. "The relationship of brain and cervical cord volume to disability in clinical subtypes of multiple sclerosis: a three-dimensional MRI study." *Acta neurologica Scandinavica* 108.6 (2003): 401-406.
- [4] Peng, Zhigang, Jia Zhong, William Wee, and Jing-huei Lee. "Automated vertebra detection and segmentation from the whole spine MR images." In *Engineering in Medicine and Biology Society, 2005. IEEE-EMBS 2005. 27th Annual International Conference of the*, pp. 2527-2530. IEEE, 2006.
- [5] Yanase, Makoto, Yukihiro Matsuyama, Kazuyoshi Hirose, Hideki Takagi, Masami Yamada, Hisashi Iwata, and Naoki Ishiguro. "Measurement of the cervical spinal cord volume on MRI." *Clinical Spine Surgery* 19, no. 2 (2006): 125-129.
- [6] Seifert, Sascha, Irina Wachter, Gottfried Schmelzle, and Rüdiger Dillmann. "A knowledge-based approach to soft tissue reconstruction of the cervical spine." *IEEE transactions on medical imaging* 28, no. 4 (2009): 494-507.
- [7] Koh, Jaehan, Taehyong Kim, Vipin Chaudhary, and Gurmeet Dhillon. "Automatic segmentation of the spinal cord and the dural sac in lumbar MR images using gradient vector flow field." In *Engineering in Medicine and Biology Society (EMBC), 2010 Annual International Conference of the IEEE*, pp. 3117-3120. IEEE, 2010.
- [8] Horsfield, Mark A., Stefania Sala, Mohit Neema, Martina Absinta, Anshika Bakshi, Maria Pia Sormani, Maria A. Rocca, Rohit Bakshi, and Massimo Filippi. "Rapid semi-automatic segmentation of the spinal cord from magnetic resonance images: application in multiple sclerosis." *Neuroimage* 50, no. 2 (2010): 446-455.
- [9] McIntosh, Chris, Ghassan Hamarneh, Matthew Toom, and Roger C. Tam. "Spinal cord segmentation for volume estimation in healthy and multiple sclerosis subjects using crawlers and minimal paths." In *Healthcare Informatics, Imaging and Systems Biology (HISB), 2011 First IEEE International Conference on*, pp. 25-31. IEEE, 2011.
- [10] Chen, Min, Aaron Carass, Jiwon Oh, Govind Nair, Dzung L. Pham, Daniel S. Reich, and Jerry L. Prince. "Automatic magnetic resonance spinal cord segmentation with topology constraints for variable fields of view." *Neuroimage* 83 (2013): 1051-1062.
- [11] De Leener, Benjamin, Samuel Kadoury, and Julien Cohen-Adad. "Robust, accurate and fast automatic segmentation of the spinal cord." *Neuroimage* 98 (2014): 528-536.
- [12] Asman, Andrew J., Frederick W. Bryan, Seth A. Smith, Daniel S. Reich, and Bennett A. Landman. "Groupwise multi-atlas segmentation of the spinal cord's internal structure." *Medical image analysis* 18, no. 3 (2014): 460-471.
- [13] Fonov, V. S., Arnaud Le Troter, Manuel Taso, Benjamin De Leener, G. Lévêque, M. Benhamou, Michaël Sdika et al. "Framework for integrated MRI average of the spinal cord white and gray matter: The MNI-Poly-AMU template." *Neuroimage* 102 (2014): 817-827.
- [14] Fradet, Léo, Pierre-Jean Arnoux, Jean-Philippe Ranjeva, Yvan Petit, and Virginie Callot. "Morphometrics of the entire human spinal cord and spinal canal measured from in vivo high-resolution anatomical magnetic resonance imaging." *Spine* 39, no. 4 (2014): E262-E269.
- [15] Kearney, Hugh, Marios C. Yiannakas, Khaled Abdel-Aziz, Claudia AM Wheeler-Kingshott, Daniel R. Altmann, Olga Ciccarelli, and David H. Miller. "Improved MRI quantification of spinal cord atrophy in multiple sclerosis." *Journal of magnetic resonance imaging* 39, no. 3 (2014): 617-623.
- [16] Weiler, Florian, Marita Daams, Carsten Lukas, Frederik Barkhof, and Horst K. Hahn. "Highly accurate volumetry of the spinal cord." In *Medical Imaging: Image Processing*, p. 941302. 2015.
- [17] Jamaludin, Amir, Meelis Lootus, Timor Kadir, and Andrew Zisserman. "Automatic Intervertebral Discs Localization and Segmentation: A Vertebral Approach." In *International Workshop on Computational Methods and Clinical Applications for Spine Imaging*, pp. 97-103. Springer International Publishing, 2015.
- [18] De Leener, Benjamin, et al. "Segmentation of the human spinal cord." *Magnetic Resonance Materials in Physics, Biology and Medicine* 29.2 (2016): 125-153.